

Relation of Color Doppler Twinkling Artifact and Scale or Pulse Repetition Frequency

Raham Bacha^{1,2*}, Syed Amir Gilani^{1,2}, Iqra Manzoor¹

¹Department of University Institute of Radiological Sciences and Medical Imaging Technologies (UIRSMIT), Faculty of Allied Health Sciences (FAHS), University of Lahore, Pakistan, ²Gilani Ultrasound Center, Afro-Asian Institute, Lahore, Pakistan

Abstract

Objective: The aim of this study is to determine the effect of scale/pulse repetition frequency (PRF) on the appearance of color Doppler twinkling artifact. **Materials and Methods:** We commenced this cross-sectional study for 20 months from November 2014 to July 2016. During routine ultrasound examination, we observed multiple case of twinkling artifact produced by renal stones, calcifications in the thyroid nodules, bony fragments and intestinal gases, etc., We observed twinkling artifact with low- and high-PRF settings in 500 different structures. A total of 500 other structures were included wherein there was no Doppler twinkling artifact produced by them, with usual optimum PRF settings. These structures were also evaluated with low- and high-PRF to determine the effect of PRF on twinkling artifact effectively. All the patients were examined according to the AIUM guideline for appropriate examination protocol. Data were collected from the observation of twinkling artifact with low- and high-PRF/scale and evaluated with the help of IBM SPSS 24 package, the results were summarized as follow. **Results:** Change in scale/PRF could not affect the twinkling artifact. The twinkling artifact observed with low-PRF was the same as seen with high-PRF. There was a significant agreement between low- and high-PRF in the production of color twinkling artifact. The kappa value of agreement was estimated as 0.96, whereas the Pearson's correlation was significant with the value of 0.001. Same twinkling artifact was created with low- and high-PRF, with no significant variation. **Conclusion:** Twinkling artifact is independent of PRF/Scale.

Keywords: Bowl gases, color commit tail, pulse repetition frequency, renal stone, scale, twinkling artifact

INTRODUCTION

Color Doppler twinkling artifact is a rapid alternation of colors posterior to a stationary echogenic structure, giving the impact of pseudo dynamicity.^[1] It appears posterior to bright focus instead of grayscale acoustic shadow that's why it is also called color comet-tail. First time it was introduced and described in 1996 by Rahmouni *et al.*, he described twinkling artifact appeared to be generated by a strongly reflecting medium composed of individual reflectors. It was concluded that color Doppler signal close to calcifications should be evaluated carefully to eliminate the twinkling artifact.^[2] Twinkling artifact is used since long to identify and confirm renal stones, calcification in the liver, thyroid nodules or fibroid, encrusted indwelling urinary stents, bowel gas, metallic foreign bodies and to some extent gallstones, choledocholithiasis, gallbladder adenomyomatosis, hepatic

bile duct hamartoma, and chronic pancreatitis.^[3-6] Nowadays, the twinkling artifact is increasingly used in the identification and differentiation of renal pelvic stones from the adjacent fats in the renal, central echo complex.^[7] Color Doppler twinkling artifact is considered useful on the diagnostic point of view, the clinical significance of this artifact is that; it can differentiate among different echogenic structures.^[8]

As for as the mechanism of this artifact is concerned, and hence the exact mechanism is still unknown, but there are two hypotheses regarding twinkling artifacts. First, which was offered by Rahmouni *et al.* suggested that when a sound beam is reflected from a rough surface, the acoustic beam split into a complex pattern with phase difference among

Address for correspondence: Dr. Raham Bacha, Gilani Ultrasound Center, Afro-Asian Institute, Lahore, Pakistan.

E-mail: dr.rahambacha@gmail.com, raham.bacha@rsmi.uol.edu.pk

Received: 03-11-2017 Accepted: 02-03-2018 Available Online: 04-02-2019

Access this article online

Quick Response Code:



Website:
www.jmuonline.org

DOI:
10.4103/JMU.JMU_129_18

This is an open access journal, and articles are distributed under the terms of the Creative Commons Attribution-NonCommercial-ShareAlike 4.0 License, which allows others to remix, tweak, and build upon the work non-commercially, as long as appropriate credit is given and the new creations are licensed under the identical terms.

For reprints contact: reprints@medknow.com

How to cite this article: Bacha R, Gilani SA, Manzoor I. Relation of color Doppler twinkling artifact and scale or pulse repetition frequency. J Med Ultrasound 2019;27:13-8.

individual wavelets caused by up and down of the surface, resulting in a long spatial pulse length. Doppler ultrasound machine assumes this complex beam pattern as moment of the reflector.^[9-11] Second – presented by Kamaya *et al.*, it is an intrinsic machine noise probably caused by random time fluctuations in the path lengths of reflected and transmitted sound waves. It was postulated that slight time fluctuations occur due to sound waves strike against a strong reflector with a rough surface. This slight time variation gives rise to aliased Doppler shifts appear as twinkling artifact.^[10-15]

Twinkling artifact is very useful in the detection and confirmation of stones, especially in the urinary tract. It has very high specificity and sensitivity as compared to relaying merely on acoustic shadow in grayscale sonography. However, the kidney is very richly supplied with blood flow, and the plexus of vessels in the renal hilum and sinus sometimes superimpose on the twinkling artifact, this changing color appearance in a vessel mimic turbulent blood flow. Intrarenal vascular abnormalities, i.e., arteriovenous fistula and intrarenal artery stenosis cause turbulence and aliasing, but this type of appearance could also be generated by color twinkling artifact caused by a rough surfaced strong reflector such as the kidney stone, foreign-body, or calcification.^[16]

A study was published to show the effect of machine settings on the twinkling artifact while using high-frequency linear array transducer and scanned Struvite stone fragments, wire mesh, and a flat surface placed in a water bath. Variable color-write priority, gray-scale gain, pulse repetition frequency (PRF), and spectral Doppler gain were varied. They observed that machine settings effect the appearance of the twinkling artifact. It was also evident that rough surface creates more twinkling artifact than a smooth surfaced reflector.^[15]

MATERIALS AND METHODS

This was a cross-sectional observational study conducted at Gilani Ultrasound Center Afroasian Institute from November 2014 to July 2016. During this period, the twinkling artifact was observed in 1000 different structures renal stones, thyroid nodule calcification, arterial wall calcifications, some of the gallstones, surgical clips, stipples, and stents. Most of the previous studies were conducted on simulators, but we selected anatomical and pathological structures in the human body. The study was aimed to look for the changes in twinkling artifact with an increase in PRF/scale. For the purpose (Toshiba Xario) with convex transducer frequency ranging from 3 to 6 MHz and linear transducer frequency ranging from 7 to 14 MHz were used. Approval was obtained from the Institutional Review Board and Ethical committee of the Gilani Ultrasound Center (Afro-Asian Institute) and the Institutional Review Board of the University of Lahore, for conducting this research.

All the individuals who have twinkling artifact in any of their organ or structure were included in this research voluntarily. They were explained the procedure and aim of the research and written informed consent was signed. All the sonographic

examinations were done under the AIUM guidelines, which are routinely observed in this department. During examination, the privacy was kept at top priority, in close circumstances. Twinkling artifact was observed in different pathological and nonpathological structures with low- and high-PRF/scale. In this study, we observed twinkling artifact in renal stones, some of the gallstones, calcification in the thyroid cystic nodules, vessel wall calcifications, bony spurs and fragments, and bowel gases etc., renal stones remain the main target of twinkling artifact in every age, gender, hypertensive, and normotensive individuals. Low-PRF and high-PRF was used to observe the superimposition renal blood flow on the twinkling artifact. PRF remains limited the depth of the image for deep structures and color box with a large depth PRF could not be increased too high but for superficial targets or color box with low-depth PRF could be increased to a great extent. We used the highest possible PRF up to 139 cm/s and the lowest PRF about 3.5 cm/s.

MS world and Excel 2016 were used for the collection and organization of data, Statistical Package for the Social Sciences version 24 (SPSS 24, IBM, Armonk, NY, United States of America) was used for the evaluation of data. Graphs and Tables were made in Excel and SPSS software. The results were summarized in the form of Graphs, Tables, and Charts. Descriptive data are explained in the form of frequency, mean and standard deviation (SD). The degree of agreement between high and low PRF was estimated with the Kappa test. The sensitivity of high PRF was calculated with the crosstabulation method.

RESULTS

Different 1000 structures were evaluated, in 1000 individuals, for twinkling artifact with high- and low-PRF/scale ranging from soft tissue to stones. Among them, 500 structures were producing twinkling artifact and 500 not twinkling artifact to ascertain the agreement of high- and low-PRF in the generation of this artifact. Structures with and without twinkling artifacts were evaluated for high- and low-PRF/scale to observe the change in the twinkling artifact. Structures we observed in this research were bone (8.7%), bone fragments (1.4%), bowel gases (3.9%), calcification in uterine fibroids (7.0%), gallstone (12.0%), intrauterine contraceptive device (2.0%), renal stone (35.2%), ureter stone (3.3%), surgical hardware (1.2%), stent (1.7%), thyroid nodule (1.6%), urinary bladder stone (3.1%), and soft tissues (18.9%) [Table 1 and Figure 1]. In the visualization of twinkling artifact, the agreement of high- and low-PRF was estimated with the Kappa test. The value of the Kappa measure of agreement was calculated as (0.96), which reflects a strong agreement. Mean twinkling artifact, which was seen with low-PRF was also observed with high-PRF [Table 2]. There was a significant correlation between twinkling with high- and low-PRF [Figure 2].

Crosstabulation of twinkling artifact observed at low- and high-PRF show that (50.2%) exhibit twinkling and (49.8%) structure remain without twinkling with high-PRF while (48.4%) presented twinkling and (51.6%) did not show

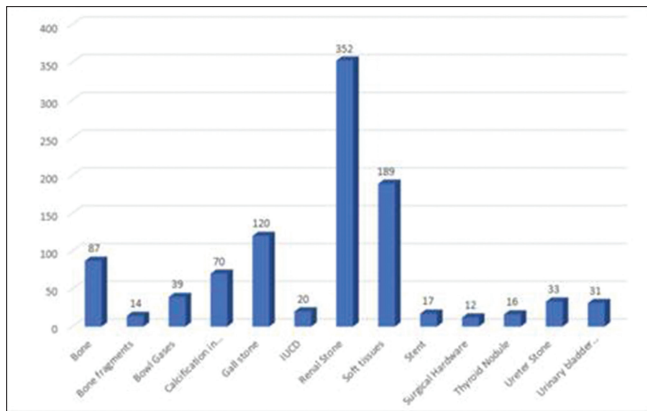


Figure 1: Percentage of all different structures evaluated for twinkling artifact with low and high pulse repetition frequency, including half the structures produced twinkling artifact and half without twinkling artifacts

twinkling with low-PRF. The crosstabulation revealed that high-PRF was 3.7% more sensitive than that of low-PRF in the production twinkling artifact. While there was a strong correlation between low and high PRF in the production of twinkling artifact *P* value is very less than the significant level 0.05 [Table 3 and Figure 3].

DISCUSSIONS

Doppler ultrasound played a very important role in the diagnosis of various pathological conditions related to hemodynamics. Along with other vascular abnormalities, color flow imaging plus grayscale has a key role in the assessment of the anatomic appearance and hemodynamics of transplanted and native kidneys. However, a variety of artifacts can be generated by the tissue moments, color Doppler twinkling artifacts are regarded as useful diagnostic signs Among these artifacts [Figure 4].^[8,17-19] Twinkling artifact was found in multiple rough surfaced, strong reflectors, i.e., calcified lesions in the liver, gallbladder adenomyomatosis, hepatic bile duct hamartoma, encrusted indwelling urinary stents, bowel gas, metallic foreign bodies, gallstones and choledocholithiasis, chronic pancreatitis, and urinary stones.^[3]

We worked on the effect of PRF on the twinkling artifact created by different structures. For this purpose, we collected data from the observation of 1000 different structures; in which 500 twinkling artifacts were evaluated for high- and low-PRF. Five hundred structures selected from different individuals having no twinkling artifacts were also evaluated with high- and low-PRF [Figures 4-7]. It was concluded from our research study twinkling artifact has no significant relation with PRF, in other words, twinkling artifact is independent of PRF/scale. We evaluated our data for the agreement of low- and high-PRF on the creation of twinkling artifact with Kappa test. It was confirmed that there was (96%) agreement between high- and low-PRF for the visualization twinkling artifact. Moreover, there was a significant correlation between low- and high-PRF in the procuction of twinkling artifact *P* value was too smaller than the level of significance. A study published

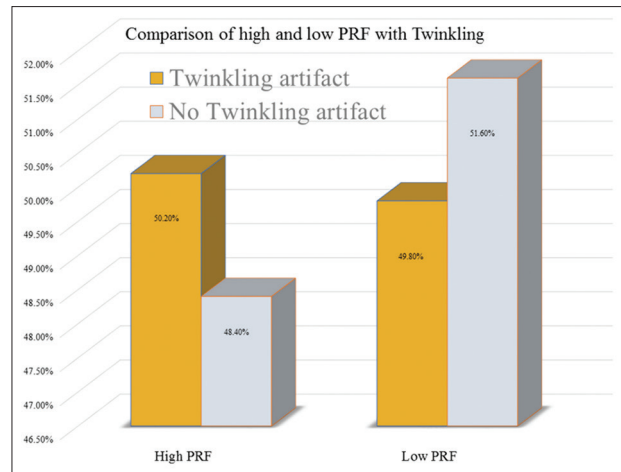


Figure 2: Correlation or agreement between twinkling artifact at low pulse repetition frequency and high pulse repetition frequency. The linear curve shows there was strong correlation between low and high pulse repetition frequency to produce color twinkling. Structures show twinkling artifact at high pulse repetition frequency were also producing twinkling at low pulse repetition frequency

Table 1: Structures evaluated for twinkling artifact

	Frequency (%)
Bone	87 (8.7)
Bone fragments	14 (1.4)
Bowl gases	39 (3.9)
Calcification in uterine fibroids	70 (7.0)
Gall stone	120 (12.0)
IUCD	20 (2.0)
Renal stone	352 (35.2)
Soft tissues	189 (18.9)
Stent	17 (1.7)
Surgical hardware	12 (1.2)
Thyroid nodule	16 (1.6)
Ureter stone	33 (3.3)
Urinary bladder stone	31 (3.1)
Total	1000 (100.0)

IUCD: Intrauterine contraceptive device

Table 2: Measure of agreement between high and low pulse repetition frequency

	Value	Asymptotic SE ^a	Approximate T ^b	Approximate significance
Measure of agreement, κ	0.960	0.009	30.378	0.000
Number of valid cases	1000			

^aNot assuming the null hypothesis, ^bUsing the asymptotic standard error assuming the null hypothesis. SE: Standard error

by Hyun Cheol Kim, in the Journal of Ultrasound in Medicine concluded that the presence of twinkling artifacts was found to be dependent on pulse repetition frequencies along with other machine parameters, i.e., focal zones, grayscale gains, and color write priorities. The article mentioned it in particularly

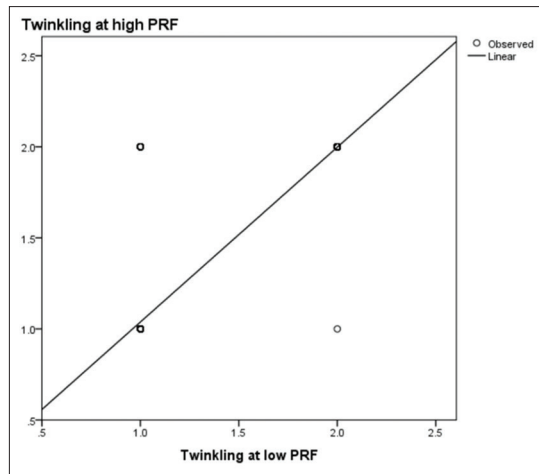


Figure 3: Comparing structures produce twinkling at low and high pulse repetition frequency. 49.8% structures produced twinkling at low pulse repetition frequency but with increase in pulse repetition frequency the twinkling was also slightly increased to 50.2%. In contrast structures having no twinkling at low pulse repetition frequency were 51.6% were slightly reduced to 48.40%

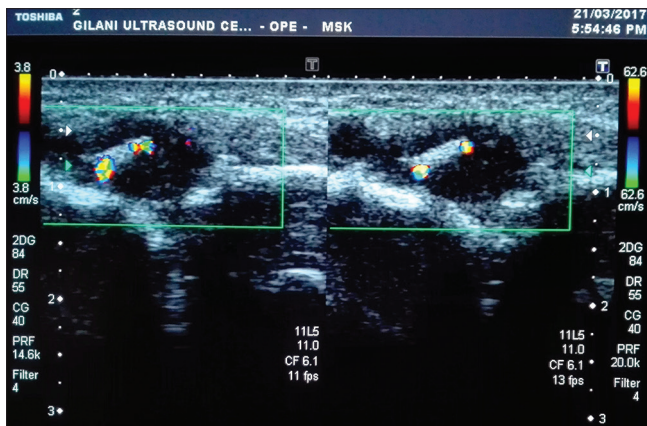


Figure 5: A bony fragment at the site of left tibial fracture, evaluated with low pulse repetition frequency 14.6 KHz (3.8 cm/s) and high pulse repetition frequency 20.0 KHz (62.6 cm/s), while keeping all the other machine settings the same. Both the images having the same twinkling artifact, confirm that twinkling artifact is pulse repetition frequency independent

strong areas of a twinkling artifact, spectral broadening is present at all pulse repetition frequencies, that's why twinkling artifact is independent of PRF.^[3] An article published by Michael Hirsch S, with the title of "Color Doppler twinkling artifact: a misunderstood and useful sign" also agree with the conclusion that twinkling artifact is independent of PRF. In this article, at the description of Figure 3; "The twinkling artifact becomes evident on color Doppler sonography, and remains visible despite an increased PRF." Which agree with our results that twinkling artifact is independent of PRF.^[20]

In this study, we observed color Doppler twinkling artifact in multiple structures, i.e., bone fragments, bowl gases, calcification in uterine fibroids, some of the gallstone, stent,

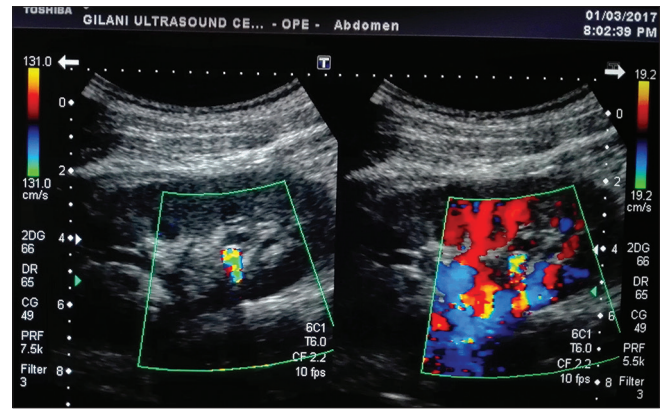


Figure 4: Right kidney with a stone having twinkling artifact evaluated with 5.5 KHz (19.2 cm/s) and 7.5 KHz (131.0 cm/s), while keeping all the other machine settings the same. In the right image with low pulse repetition frequency (scale) the twinkling is superimposed by colors from the blood flow. On the left side image with high pulse repetition frequency (scale) shows only twinkling from the stone but the low Doppler shift blood flow is subtracted

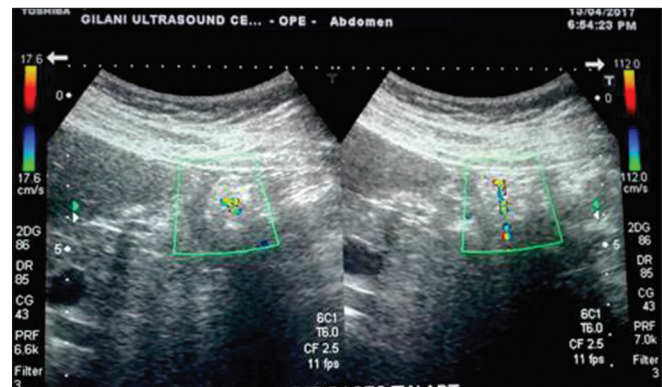


Figure 6: Twinkling artifact produced by gases in the gastrointestinal tract, evaluated with high pulse repetition frequency 7.0 KHz (112 cm/s) and low pulse repetition frequency 6.6 KHz (17.6 cm/s), while keeping all the other machine settings the same. With high pulse repetition frequency (scale) there is twinkling artifact while there is no twinkling detected with low pulse repetition frequency (scale), which ultimately conclude that twinkling artifact is pulse repetition frequency (scale) independent

surgical hardware, thyroid nodules, ureter stones, urinary bladder stones, and a maximum number of twinkling artifact was found in renal stones (35.2%). Winkling artifact was found in hepatic bile duct hamartoma, calcified lesions in the liver, chronic pancreatitis, gallbladder adenomyomatosis, gallstones and choledocholithiasis, bowel gas, and metallic foreign bodies, encrusted indwelling urinary stents and most commonly in urinary tract stones. Another study reveals that the majority of the stones were found in the urinary tract and with the help of Doppler, the diagnostic sensitivity wit increased to (97%). Our results were regarding the appearance of twinkling artifact agree with international studies.^[7,21]

High-PRF was seem to be more sensitive than low-PRF, especially in bony fragments, bowl gases, and urinary tract

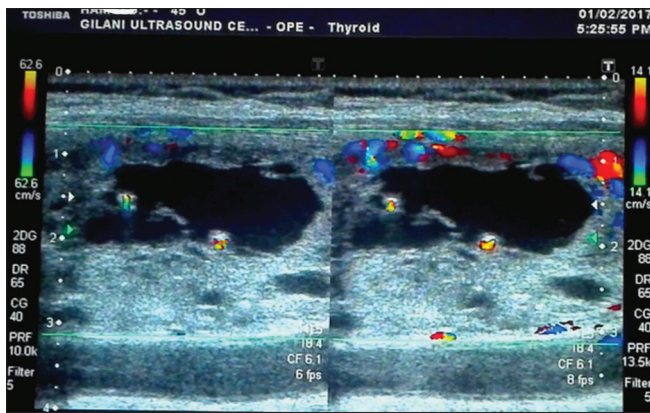


Figure 7: Calcification in the thyroid colloidal nodule shows twinkling artifact, evaluated with 10 KHz (62.6 cm/s) and 13.5 KHz (14.1 cm/s), while keeping all the other machine settings the same. High and low pulse repetition frequency have the same twinkling artifact

Table 3: Crosstabulation of twinkling artifact observed at low and high pulse repetition frequency

	Twinkling at low PRF		Total
	Yes	No	
Twinkling at high PRF			
Yes			
Count	483	19	502
Percentage within twinkling at high PRF	96.2	3.8	100.0
Percentage within twinkling at low PRF	99.8	3.7	50.2
No			
Count	1	497	498
Percentage within twinkling at high PRF	0.2	99.8	100.0
Percentage within twinkling at low PRF	0.2	96.3	49.8
Total			
Count	484	516	1000
Percentage within twinkling at high PRF	48.4	51.6	100.0
Percentage within twinkling at low PRF	100.0	100.0	100.0

PRF: Pulse repetition frequency

stones. Some of these structures had low or even no twinkling artifact with low-PRF, but the twinkling sign was increased and became visible with high-PRF. That's why twinkling was observed in (49.8%) of all the structures with low-PRF and was increased to (50.2%) with high-PRF. A study published by Kamaya *et al.*, in the American Journal of Radiology, concluded that the appearance of color twinkling artifact is highly dependent on machine settings. System noise measured on a flat surface generates a band limited Doppler shift on spectral displays with a mean frequency shift of 0 Hz and a mean (\pm SD) absolute fluctuation of 86 ± 10 Hz over a PRF range of 1250–10,000 Hz. Rough surfaces increase the spectral bandwidth.^[15]

CONCLUSION

Twinkling artifact is independent of PRF/scale, it depends on the structure's surface contour. Color Doppler twinkling artifact could be produced the same way with the use of high-PRF or low-PRF. We can therefore get a better twinkling artifact from a structure situated among the vessels with high PRF.

Recommendations

It is recommended to have further studies on high PRF/scale in the evaluation of renal stone to avoid possible superimposition of Color from the blood vessels, aliasing from stenosis or mosaic flow pattern from arteriovenous fistula on the twinkling artifact.

Acknowledgments

I (Dr. Raham Bacha) would first like to thank my mother, without her continuous support, encouragement and prayers, I would have never been able to achieve my goals. Special thanks to all the staff members of Gilani Ultrasound Center Afro-Asian institute, especially Zain-Ul-Hasan, Hafiz Muhammad Umar, Qareeb-Ur-Rahman and Ahmed.

Financial support and sponsorship

Nil.

Conflicts of interest

There are no conflicts of interest.

REFERENCES

- Hirsch M, Palavecino T, León B. Color Doppler twinkling artifact: A misunderstood yet useful sign. *Rev Chil Radiol* 2011;17:82-4.
- Ahmad SK, Abdallah MM. The diagnostic value of the twinkle sign in color Doppler imaging of urinary stones. *Egypt J Radiol Nucl Med* 2014;45:569-74.
- Kim HC, Yang DM, Jin W, Ryu JK, Shin HC. Color Doppler twinkling artifacts in various conditions during abdominal and pelvic sonography. *J Ultrasound Med* 2010;29:621-32.
- Tchelepi H, Ralls PW. Color comet-tail artifact: Clinical applications. *AJR Am J Roentgenol* 2009;192:11-8.
- Tsao TF, Kang RJ, Tyan YS, Gueng MK, Lee T, Lee SK, *et al.* Color Doppler twinkling artifact related to chronic pancreatitis with parenchymal calcification. *Acta Radiol* 2006;47:547-8.
- Jeon SJ, Yoon SE. Color Doppler twinkling artifact in hepatic bile duct hamartomas (von Meyenburg complexes). *J Ultrasound Med* 2006;25:399-402.
- Mitterberger M, Aigner F, Pallwein L, Pinggera GM, Neururer R, Rehder P, *et al.* Sonographic detection of renal and ureteral stones. Value of the twinkling sign. *Int Braz J Urol* 2009;35:532-9.
- Rubens DJ, Bhatt S, Nedelka S, Cullinan J. Doppler artifacts and pitfalls. *Ultrasound Clin* 2006;1:79-109.
- Rahmouni A, Bargoin R, Herment A, Bargoin N, Vasile N. Color Doppler twinkling artifact in hyperechoic regions. *Radiology* 1996;199:269-71.
- Choi MJ, Cho CH, Kang G, Yang J. Color Doppler twinkling artifact: Possible mechanisms and clinical potential. *Biomed Eng Lett* 2014;4:41-54.
- Dillman JR, Kappil M, Weadock WJ, Rubin JM, Platt JF, DiPietro MA, *et al.* Sonographic twinkling artifact for renal calculus detection: Correlation with CT. *Radiology* 2011;259:911-6.
- Lee JY, Kim SH, Cho JY, Han D. Color and power Doppler twinkling artifacts from urinary stones: Clinical observations and phantom studies. *AJR Am J Roentgenol* 2001;176:1441-5.
- Gao J, Hentel K, Rubin JM. Correlation between twinkling artifact and color Doppler carrier frequency: Preliminary observations in renal calculi. *Ultrasound Med Biol* 2012;38:1534-9.
- Tsao TF, Kang RJ, Gueng MK, Tyan YS, Lin YC, Lee SK. Color Doppler

- twinkling artifact and clinical use. *J Med Ultrasound* 2009;17:157-66.
15. Kamaya A, Tuthill T, Rubin JM. Twinkling artifact on color Doppler sonography: Dependence on machine parameters and underlying cause. *AJR Am J Roentgenol* 2003;180:215-22.
 16. Gao J, Ng A, Dang MN, Min R. Flow turbulence or twinkling artifact? A primary observation on the intrarenal color doppler sonography. *Clin Imaging* 2010;34:355-60.
 17. Krumme B. Renal doppler sonography – Update in clinical nephrology. *Nephron Clin Pract* 2006;103:c24-8.
 18. Werner M, Osadchy A, Plotkin E, Berheim J, Rathaus V. Increased detection of early vascular abnormalities after renal biopsies by color Doppler sonography. *J Ultrasound Med* 2007;26:1221-6.
 19. Park SB, Kim JK, Cho KS. Complications of renal transplantation: Ultrasonographic evaluation. *J Ultrasound Med* 2007;26:615-33.
 20. Hirsch M, Palavecino T, León B. Color Doppler twinkling artifact: A misunderstood and useful sign. *Rev Chil Radiol* 2011;17:82-4.
 21. Masch WR, Cohan RH, Ellis JH, Dillman JR, Rubin JM, Davenport MS. Clinical effectiveness of prospectively reported sonographic twinkling artifact for the diagnosis of renal calculus in patients without known urolithiasis. *AJR Am J Roentgenol* 2016;206:326-31.